




Single NeVa Rescues Kissing Retrievers In Carotid T Occlusion

NeVa™ 6.0 x 44 mm



Dr. Alejandro Tomasello

Vall d'Hebron Hospital
Barcelona/ SPAIN

Presentation

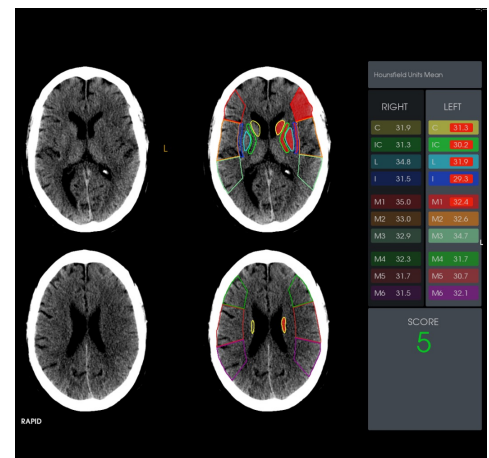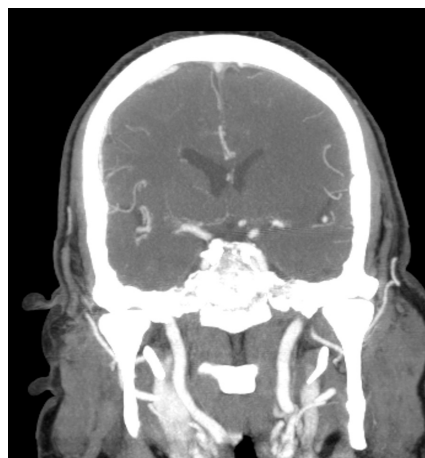
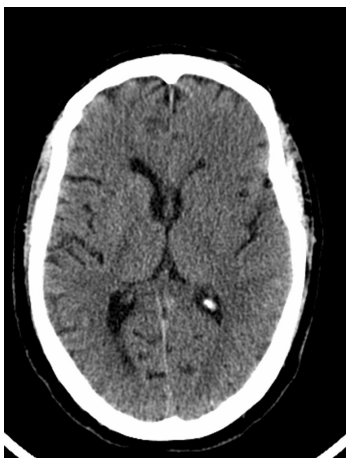69 year old male patient presented with a NIHSS of 22, two and a half hours after symptom onset.

Imaging confirmed occlusion of distal left internal carotid artery (carotid-T occlusion).

NIHSS at Admission

1a Level of Consciousness	0
1b LOC Questions	2
1c LOC Commands	2
Best Gaze	2
Visual Fields	2
Facial Palsy	2
5a Left Motor Arm	0
5b Right Motor Arm	4
6a Left Motor Leg	0
6b Right Motor Leg	4
Limb Ataxia	0
Sensory	1
Best Language	3
Dysarthria	0
Extinction and Inattention	0
Total	22

Pre-Op CT

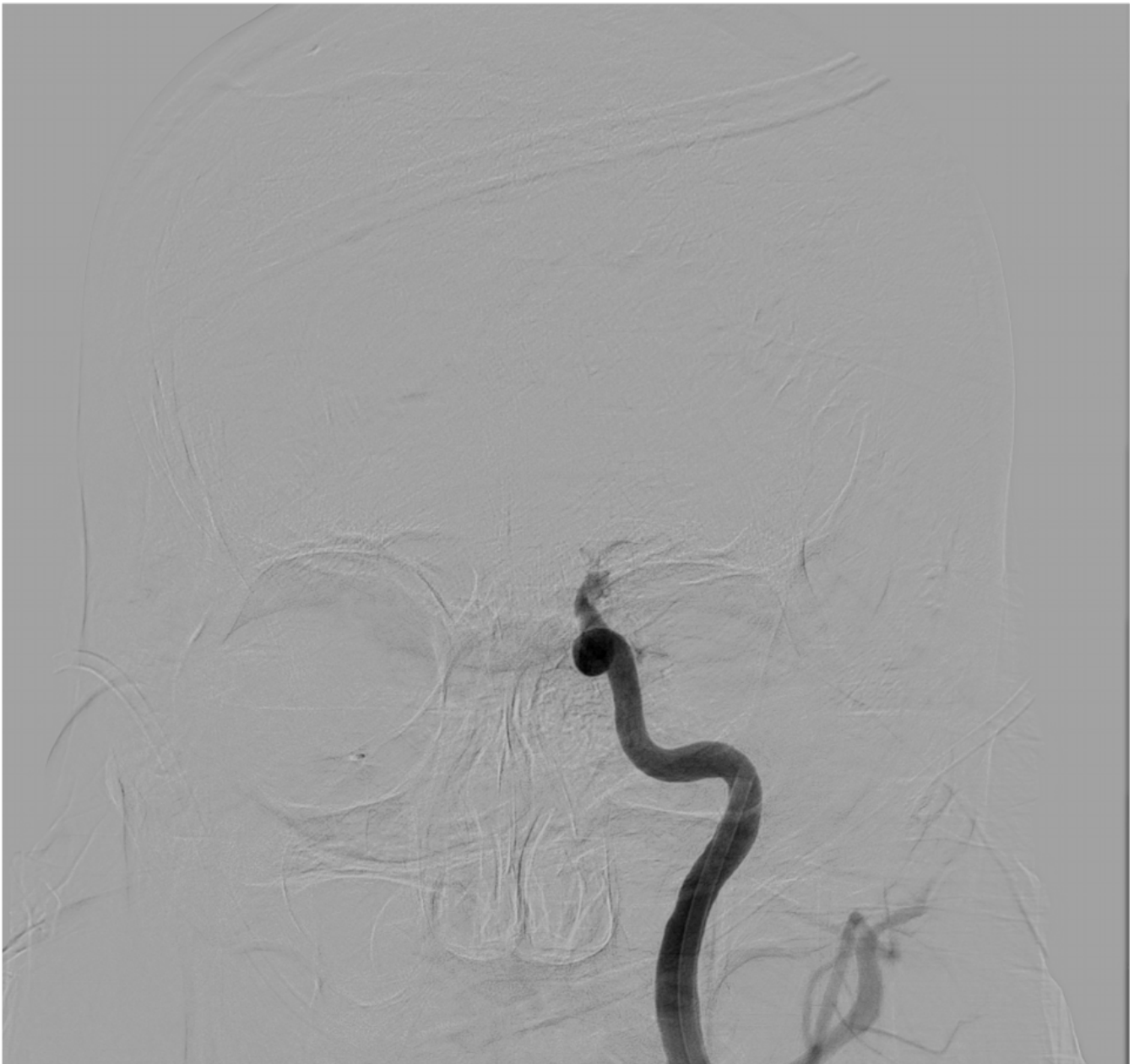

The Procedure

Dr Tomasello and the Vall d'Hebron team decided to treat the patient by administering IV-tPA (9 mg bolus and 81 mg) and endovascular thrombectomy. Femoral approach was used for access and the team decided to do co-aspiration (Solubra) as a flow control strategy. CTA confirmed the occlusion of the terminal left ICA and ipsilateral A2 branches.

During the procedure, the first two passes in the ICA were done using 2 conventional stent retrievers with the "kissing technique". When these passes did not give the desired result, a NeVa 6 x 44 mm was used to achieve full recanalization (TICI 3) in a single pass. A final pass was done to clear up the ipsilateral A2 occlusion.

Angio Showing the CAROTID T Occlusion

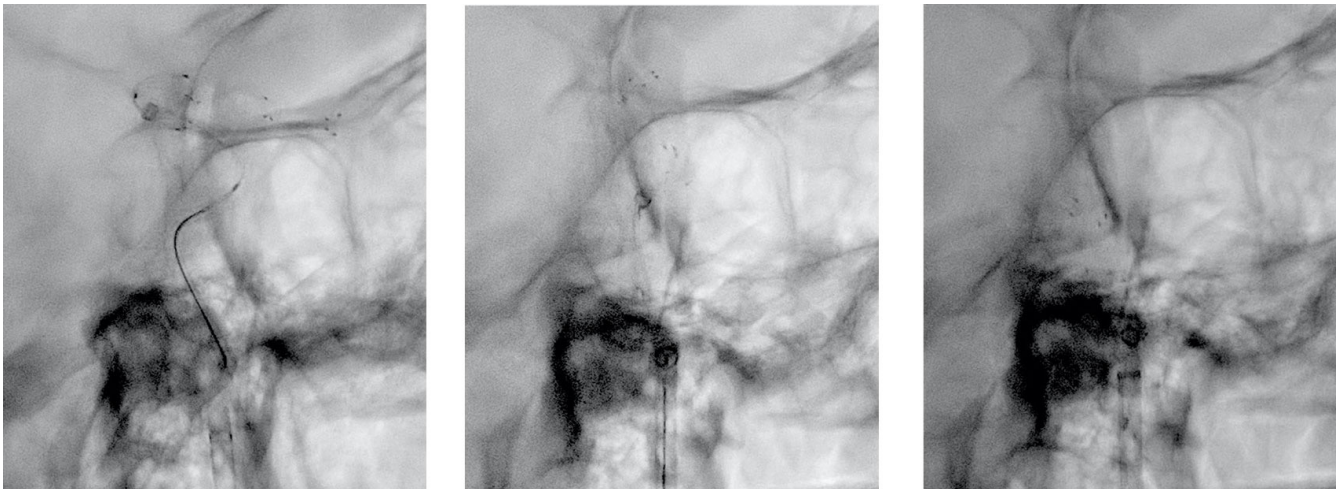

1st pass: "Kissing" or "Overlapping Stent" Technique Using 2 Stent Retrievers + Co-aspiration

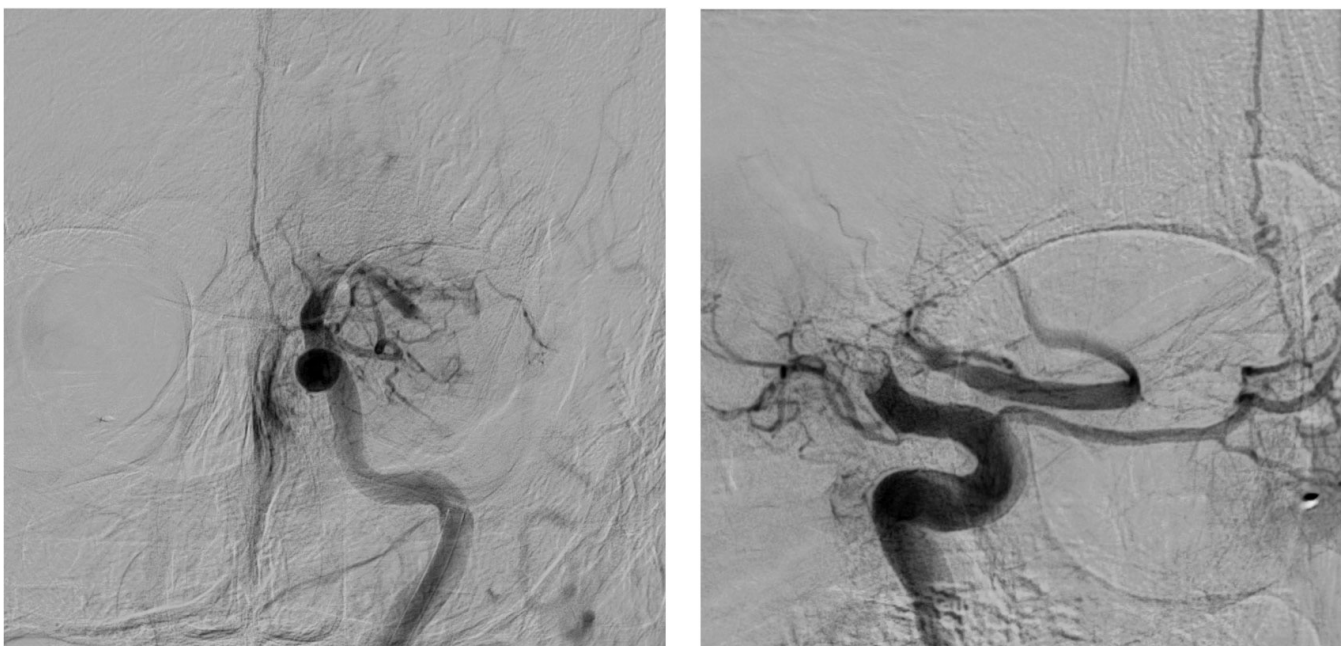
Treatment in the ICA: first 2 passes using "kissing technique" with 2 conventional stent retrievers

Due to the typical high clot burden expectation from a Carotid T occlusion, Dr Tomasello initially decided to use 2 conventional stent-retrievers (6 x 40 mm & 4.5 x 40 mm) and employed the "kissing technique".

The size of the DAC used for co-aspiration during all three passes was: 0.071" x 132 cm.



Angio Showing Recanalization After The 1st Pass

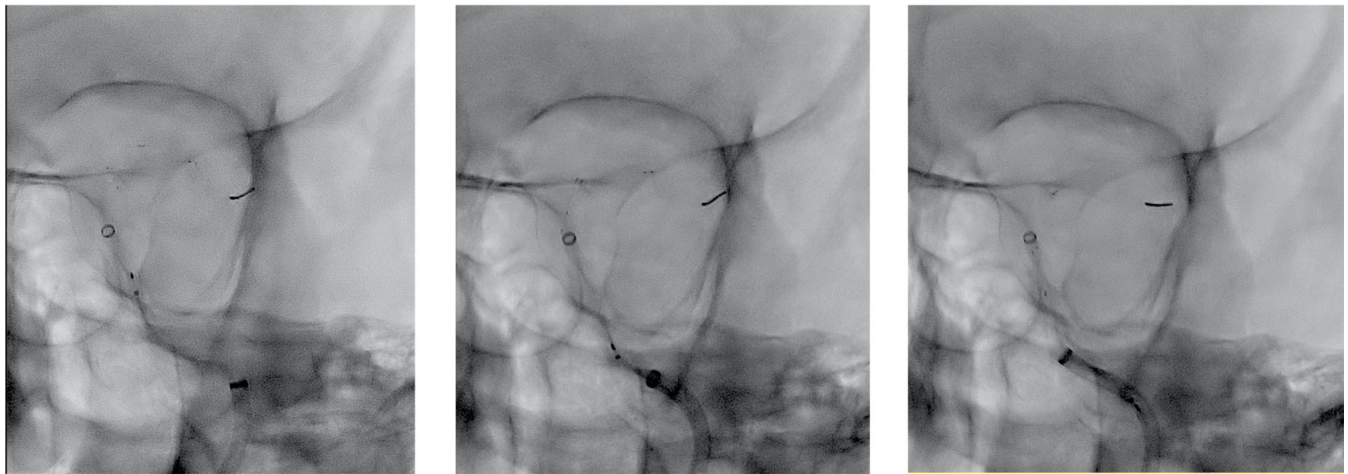


3rd pass: NeVa 6 x 44 mm + co-aspiration in Left MCA

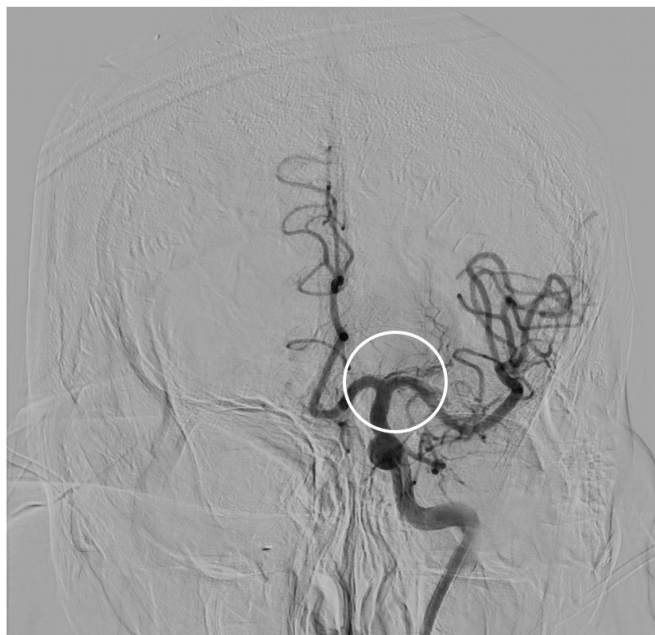Treatment in the ICA: 3rd pass using NeVa

Following the failure of the first two passes at achieving recanalization, Dr Tomasello decided to give the largest NeVa (6.0 x 44 mm) a try on its own. Full recanalization (TICI 3) was possible with a single NeVa pass.

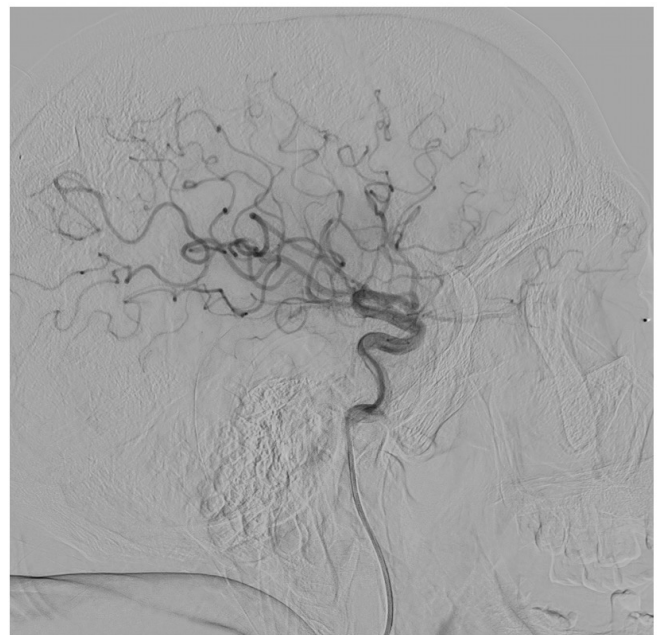
The size of the DAC used for co-aspiration during all three passes was: 0.071" x 132 cm.



Angio Showing Recanalization After the 3rd Pass with NeVa



AP View



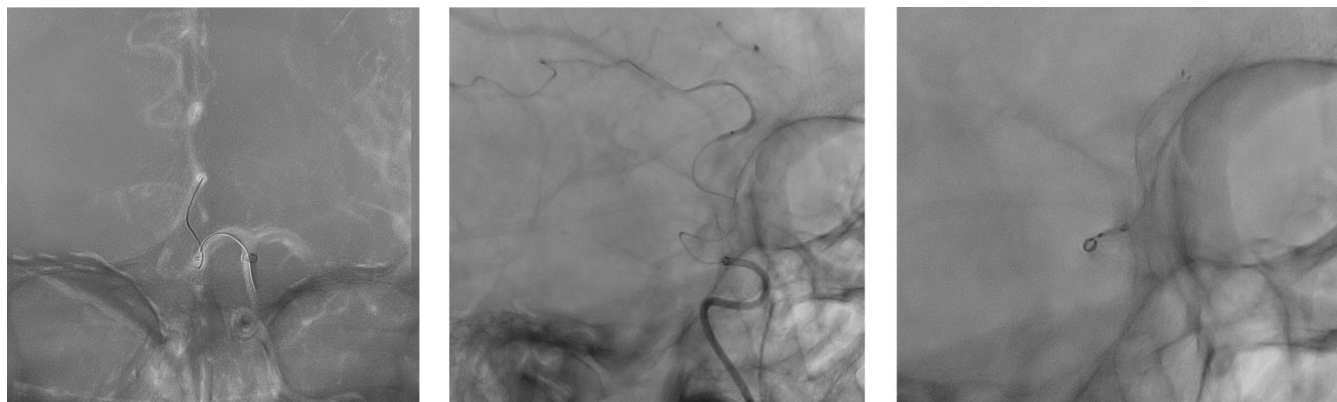
Lateral View

ACA (A2) Pass: Smaller Stent-Retriever + Co-Aspiration

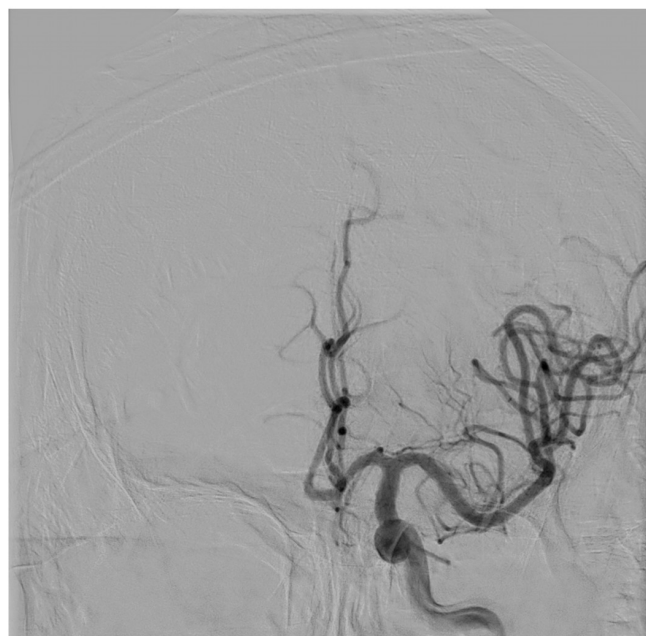Treatment in the ICA:

A smaller stent-retriever was used in this more distal branch and full recanalization (TICI 3) was possible.

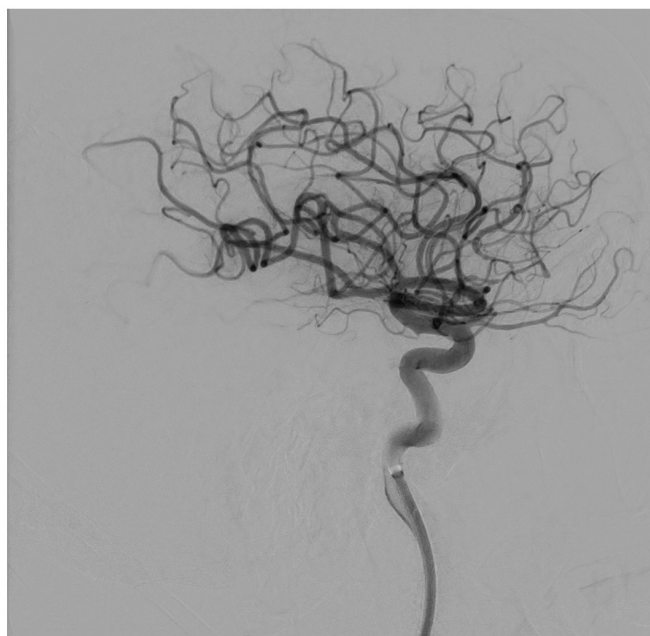
The size of the DAC used for co-aspiration was: 0.035" x 160 cm.



Angio Showing Recanalization of Left ACA

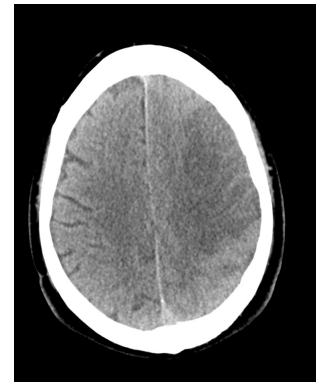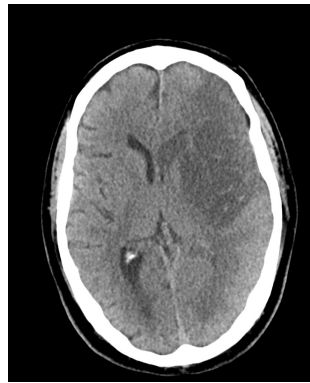
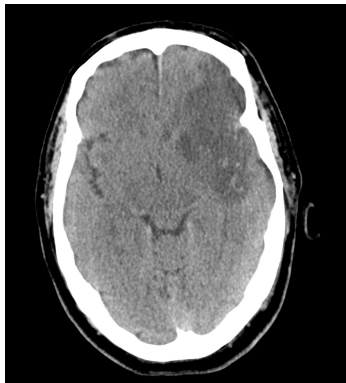


AP View



Lateral View

Post Op CT



Procedural Statistics

Last Seen Well	01:30
Realization of symptoms	Awake stroke
Door (admission)	06:00
CT/MRI	Direct to angiosuite
IV-TPA	06:25
Arrival to angio suite	06:37
Femoral puncture	06:25
Recanalization	08:00

Door-to-Puncture: 25 minutes	Door-to-Recan: 120 minutes (2 hrs)
Puncture-to-Recan: 95 minutes	

Last-Seen-Well-to-Recan:
390 minutes
(6 ½ hrs)

Clinical Success

24 hour NIHSS of the patient was 21.

At VESALIO, we feel blessed to be part of the stroke field where together with these dedicated physicians, we can make an incredible impact on people's lives.

Thank you Vall d'Hebron!

24 hour- NIHSS

1a Level of Consciousness	0
1b LOC Questions	2
1c LOC Commands	2
Best Gaze	1
Visual Fields	2
Facial Palsy	2
5a Left Motor Arm	0
5b Right Motor Arm	4
6a Left Motor Leg	0
6b Right Motor Leg	4
Limb Ataxia	0
Sensory	1
Best Language	3
Dysarthria	0
Extinction and Inattention	0
Total	21